



SRI RAMAKRISHNA  
HOSPITAL

# pulse

*Happenings at Sri Ramakrishna...*



As we step into the month of June, we reaffirm our commitment to delivering compassionate, accessible, and advanced healthcare services to the community. At Sri Ramakrishna Hospital, every milestone we achieve is driven by our mission to serve humanity with dedication, integrity, and excellence. The unwavering efforts of our doctors, nurses, healthcare professionals, and support teams continue to strengthen the trust placed in us by thousands of families.

This month also brings awareness to important global health observances such as World Brain Tumour Day and World Blood Donor Day. These occasions remind us of the importance of early diagnosis, advanced neurological care, and the life-saving impact of voluntary blood donation. Through awareness initiatives and community engagement programs, we continue to encourage preventive healthcare and social responsibility among the public.

As healthcare continues to evolve, we remain focused on innovation, patient-centered care, and clinical excellence. Together, let us continue to build a healthier society through compassion, awareness, and collective service.




**Dr. Sundar Ramakrishnan**  
Managing Trustee

The month of June highlights significant healthcare awareness initiatives that encourage us to strengthen our commitment towards specialized and preventive medical care. At Sri Ramakrishna Hospital, our medical teams continuously strive to provide evidence-based treatment supported by advanced technology, clinical expertise, and compassionate patient care.

On World Brain Tumour Day, we recognize the importance of neurological health and the need for timely diagnosis and multidisciplinary treatment approaches for brain tumour patients. Increasing public awareness and encouraging early medical consultation can greatly improve treatment outcomes and quality of life for patients and families.

We also observe World Blood Donor Day, a reminder of the invaluable role voluntary blood donors play in saving lives every day. Blood donation remains a vital support for emergency care, surgeries, cancer treatment, and critical medical interventions. We extend our heartfelt gratitude to all donors and encourage more individuals to participate in this noble act of humanity and service.



**Dr. S. Rajagopal**  
Medical Director

## Editorial Team

**Dr. N. Loganathan**  
Pulmonologist

**Dr. S. Prahadeeshwaran**  
General Manager - Public Relations

**Mr. Santhosh Vijayakumar**  
Head - Corporate Relations & International Affairs

## SRI RAMAKRISHNA HOSPITAL INTERNATIONAL NURSES DAY CELEBRATIONS - 12.05.2026

Our hospital celebrated International Nurses Day with great enthusiasm and gratitude, recognizing the invaluable contribution of our nursing professionals who serve with dedication, compassion, and commitment every day. The celebration was organized to honor the selfless efforts of nurses and acknowledge their vital role in patient care and healthcare excellence. The event featured vibrant cultural performances by the nursing staff, creating a joyful and energetic atmosphere across the institution. The performances reflected teamwork, talent, and the strong spirit of the nursing fraternity, making the celebration memorable for everyone who attended.



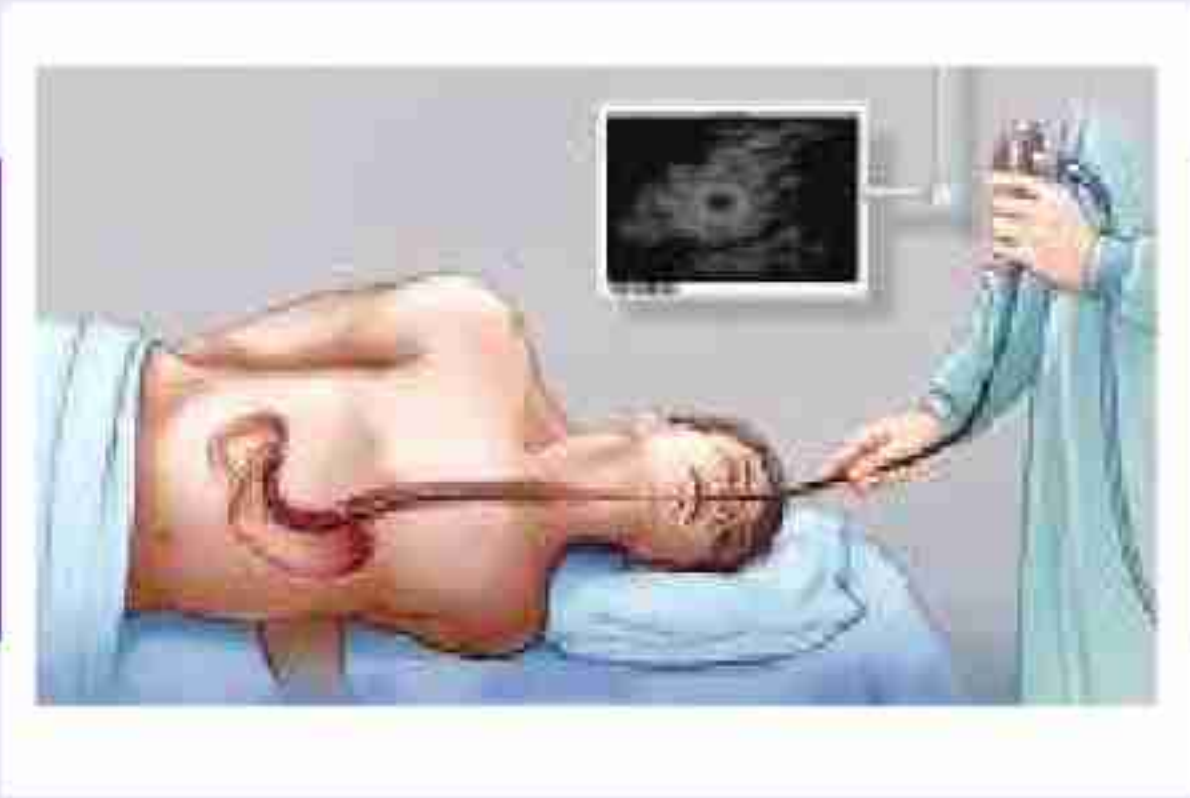
As part of the celebration, special recognition was given to the best-performing nurses for their exceptional service, professionalism, and commitment towards patient care. Their hard work and dedication were appreciated and applauded by the management, doctors, and fellow staff members, inspiring others to continue delivering compassionate healthcare services. A special tribute was also paid to Florence Nightingale, the pioneer of modern nursing, by releasing balloons into the sky as a symbol of respect, gratitude, and remembrance. The celebration concluded on a meaningful note, reflecting the hospital's continued appreciation and support for the nursing community.

## SRI RAMAKRISHNA HOSPITAL WORLD NO TOBACCO DAY - 30.05.2026

Sri Ramakrishna Hospital observed **World No Tobacco Day 2026** with a meaningful awareness programme aimed at promoting a tobacco-free society. The event featured the launch of a Digital Spin Wheel Based Awareness Activity that educated the public on the harmful effects of tobacco use and emphasized the importance of healthy living. The awareness initiative was officially launched by Shri.N.Kannan IPS, Commissioner of Police, Coimbatore City, Dr. Sundar Ramakrishnan, Managing Trustee, SNR Sons Charitable Trust, Dr.P.Guhan, Director & Consultant Medical Oncologist, along with other Oncology doctors.



The programme witnessed active participation from doctors, staff, and attendees who joined together to spread awareness on cancer prevention and wellness. The occasion was also graced by Shri. C. V. Ramkumar, Chief Executive Officer, Shri. D. Mahesh Kumar, Chief Administrative Officer, Dr. S. Rajagopal, Medical Director, and Dr. S. Alagappan, Medical Superintendent. The initiative reflected the institution's continued commitment towards preventive healthcare, social responsibility, and community well-being.



## Endoscopic ultrasound Guided Rendezvous procedure in a case of Lower CBD stricture secondary to CA Pancreas with obstructive jaundice

69 years old male known case of CAD/SHTN/DM presented with complaints of progressive yellowish discoloration of sclera, high colored urine since 1 month and complaints of generalized itching and passage of clay colored stools since 15 days. Weight loss of 4 kg recently and mild abdominal pain in the epigastric region. No nausea, vomiting, fever or abdominal distention. no history of any major illness in the past.

On Examination vitals were normal and patient was found to have icterus and mild pallor. No edema or lymphadenopathy. On systemic examination patient had Mild epigastric tenderness otherwise no organomegaly or ascites /other systems were normal.

**INVESTIGATIONS:** Relevant blood investigation revealed deranged LFT ( TB -5.3, DB -4.1, IDB-1.2, SGOT-70, SGPT-50, ALKP-421, GGT-278), other parameters were within normal limits. Oncogenic marker CA 19.9 - <1.4 (normal). USG Abdomen showed Dilated CBD / IHBR dilated, suggested further evaluation. All the above investigations were suggestive of Obstructive jaundice, hence patient was planned for MRCP to make more accurate diagnosis. MRCP abdomen revealed Stricture in the distal CBD, Severely dilated CHD and IHBR, Mass lesion in the body of pancreas compressing splenic vein and portal confluence – possible carcinoma of pancreas with Rim enhancing liver lesion in segment 4 of liver? Metastasis, Peripancreatic and peri splenic fat stranding – ? acute pancreatitis.

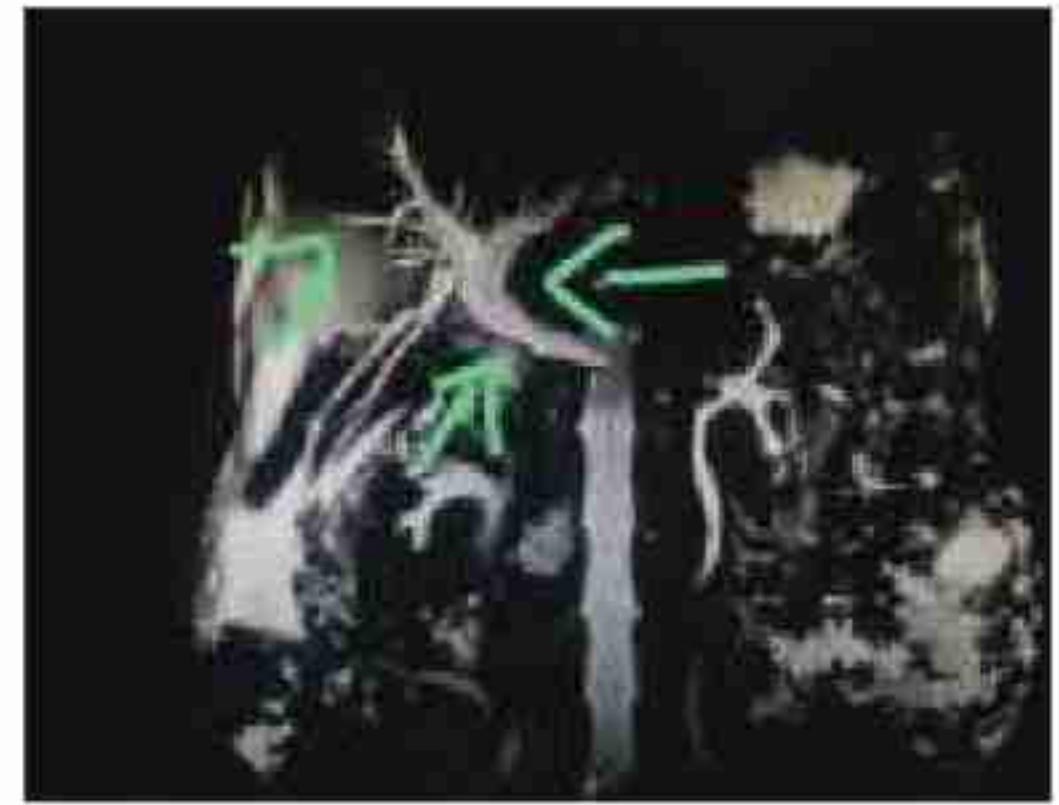


Image 1: Showing dilated IHBR and CBD with smooth narrowing of CBD

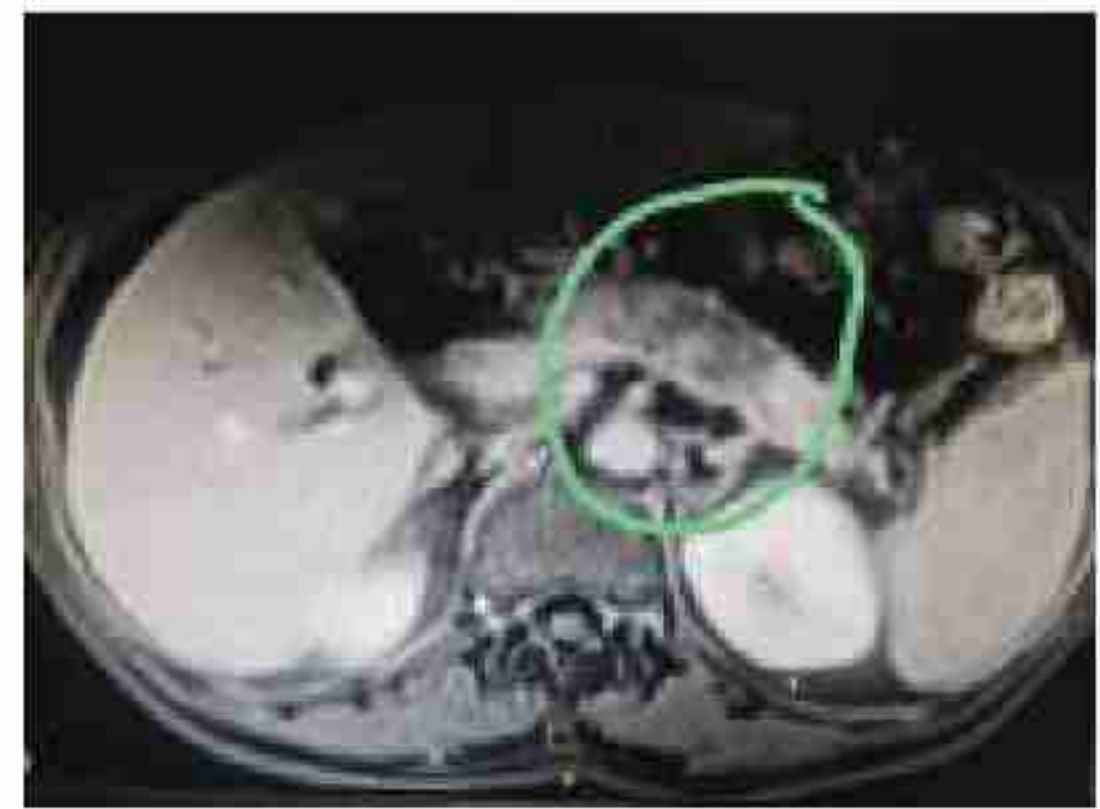

Image 2: Representing tumor in the body of pancreas

**MANAGEMENT:** After analyzing laboratory investigations and imaging patient was planned for Endoscopic ultrasound (EUS) guided Fine needle biopsy (FNB) followed by biliary drainage. Patient underwent diagnostic EUS which showed Hypoechoic mass lesion in the proximal body of pancreas of size 3.3x2cms. FNB was done using boston scientific 22G acquire FNB needle. Following FNB, Endoscopic Retrograde Cholangio Pancreatography (ERCP) and biliary drainage was attempted but procedure was deferred as CBD cannulation failed due to tight lower CBD stricture.

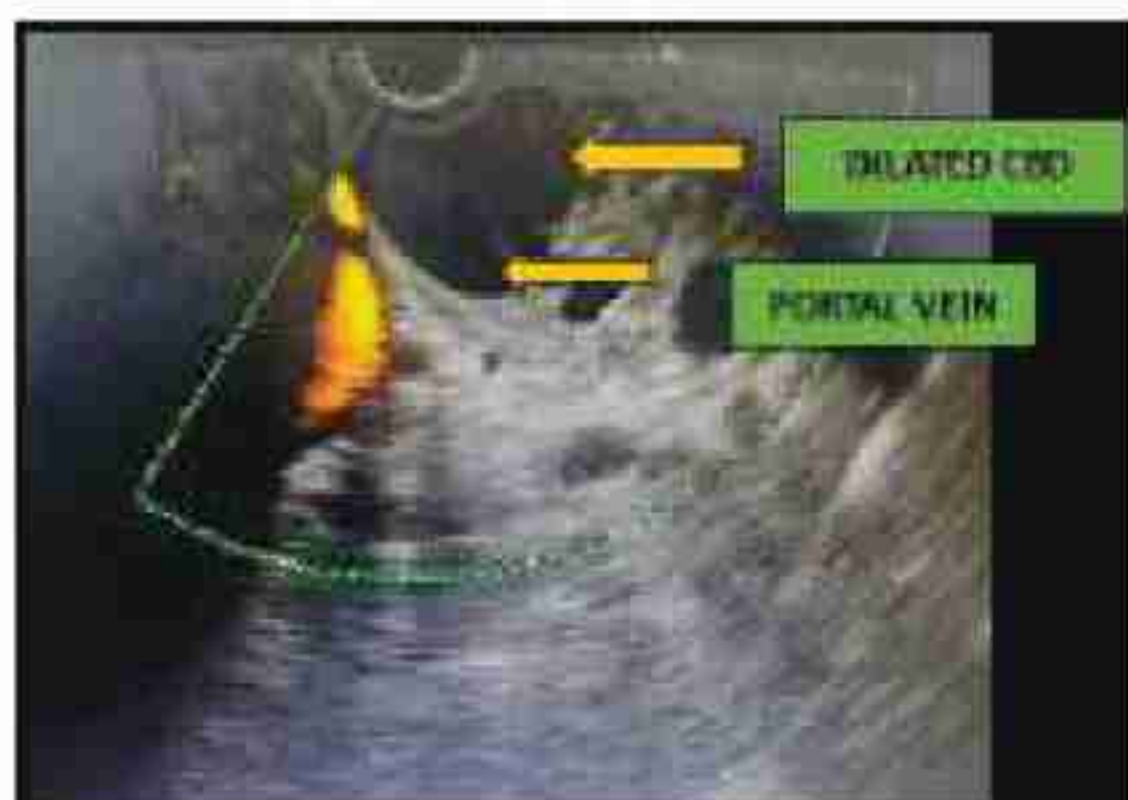

Image 3: Image Representing Dilated CBD

Since ERCP failed, other options left with us were PTBD or surgical biliary drainage or EUS guided biliary drainage. After considering the advantages and disadvantages of all the options, finally we decided to proceed with EUS guided rendezvous procedure.

#### STEPS OF THE PROCEDURE

- Diagnostic EUS at D1 station
- CBD identified and punctured with 19 G FNA Needle
- Guidewire negotiated through ampulla
- Cholangiogram revealed dilated CBD/IHBR with long lower CBD stricture
- RENDEZVOUS technique applied and fully covered metal stent was deployed.

Post procedure was uneventful Bilirubin levels came down significantly, Biopsy revealed Adenocarcinoma with the background of atrophic pancreatitis. Patient became symptomatically better and hence discharged.

**DISCUSSION:** EUS guided biliary drainage by Rendezvous technique is an advanced method for therapeutic biliary drainage. It is generally done when standard ERCP fails due to complex biliary obstruction such as malignant tumor infiltration / benign or tight malignant CBD strictures which is seen in 7-13% of patients. Traditionally, these

patients were managed with percutaneous transhepatic biliary drainage. However, the EUS guided RENDEZVOUS TECHNIQUE has emerged as a newer and less invasive advancement in interventional gastroenterology for complex biliary blockage. The procedure requires technical expertise and meticulous endoscopic skills.

In this technique the bile duct is punctured under Endoscopic ultrasound guidance, and a guide wire is advanced through the CBD and papilla into the duodenum. A duodeno scope is positioned at the papilla, where the exiting wire is captured with a snare and pulled through the accessory channel. The 'Rendezvous' between the guide wire and the endoscope allows over-the-wire access to the CBD using a papillotome, improve the access to CBD while reducing procedural complications.

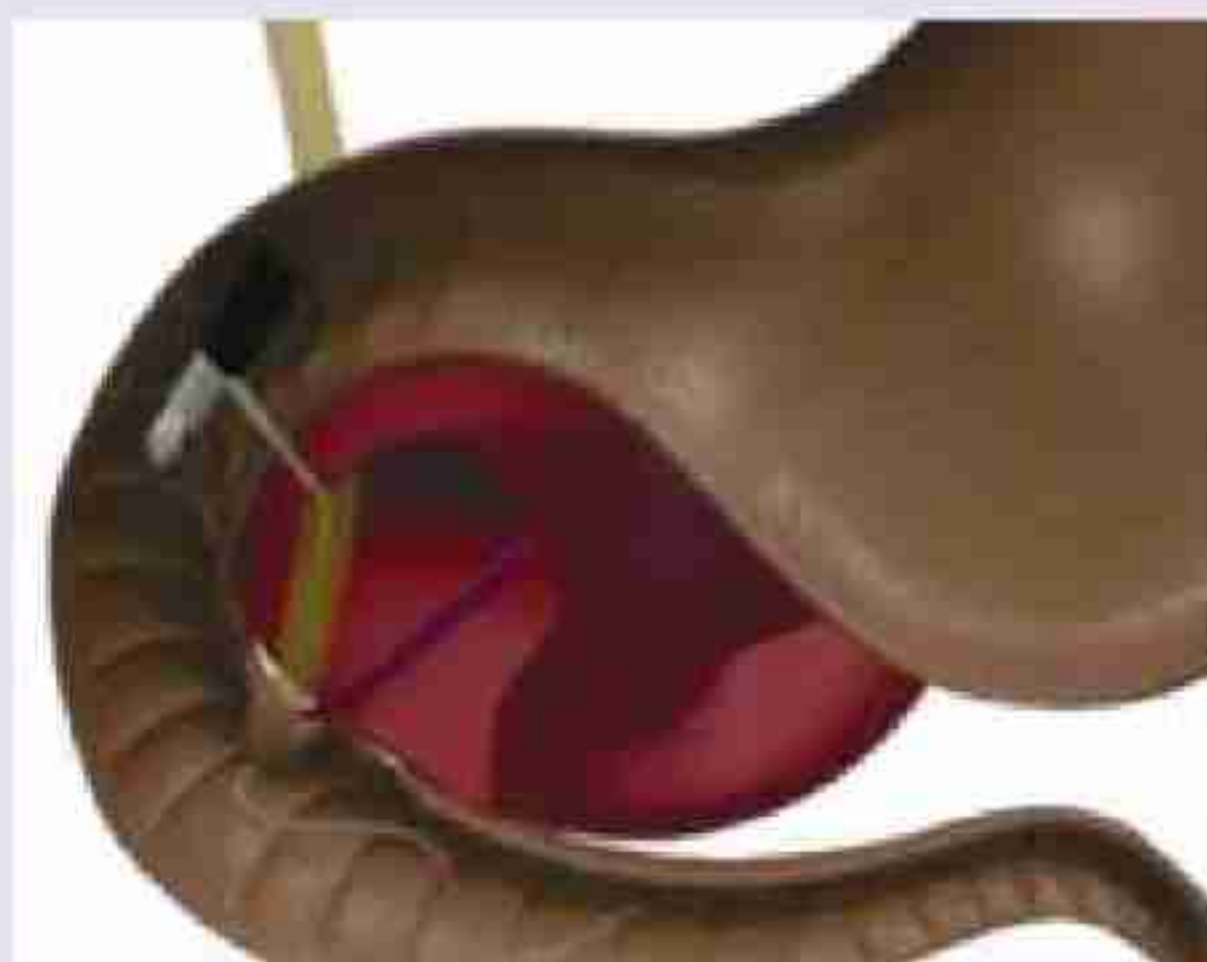

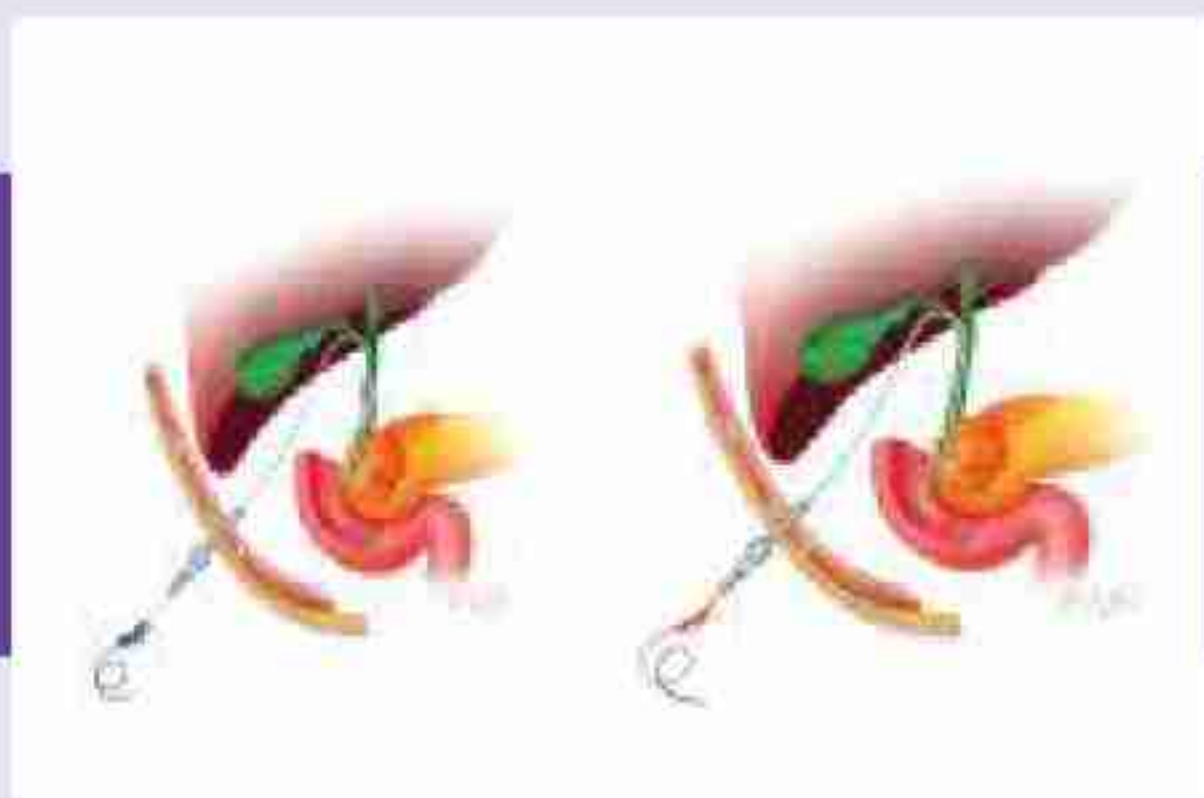
Image 4 : Depicting Scope Guided Puncture of Bile Duct

**CONCLUSION:** EUS guided Rendezvous procedure is an alternative, advanced and comparatively less invasive technique in which biliary drainage is achieved in complex biliary obstruction when conventional ERCP method fails.

**Dr. M. MURUGESH**  
MD., DM., (GASTRO),

Consultant Medical  
Gastroenterologist & Hepatologist





## Recurrent Cholangitis Due to Forgotten Biliary Stent with Benign Mid-Common Bile Duct Stricture Managed by SpyGlass-Guided Laser Lithotripsy: A Case Report

**Abstract:** Retained biliary stents are a well-recognized cause of recurrent cholangitis and secondary biliary complications<sup>1</sup>. We report a 72-year-old male with a history of endoscopic retrograde cholangiopancreatography (ERCP) and plastic stent placement for choledo cholithiasis, who was lost to follow-up and subsequently developed recurrent cholangitis due to stent occlusion, stone formation, and a benign mid-common bile duct (CBD) stricture. Definitive management was achieved using SpyGlass cholangioscopy-guided laser lithotripsy, stricture evaluation with targeted biopsy, and complete duct clearance, followed by laparoscopic cholecystectomy. This case highlights the complications of forgotten biliary stents and underscores the role of advanced cholangioscopy in complex biliary disease<sup>2</sup>.

**Keywords:** Forgotten biliary stent; Cholangitis; Choledocholithiasis; Benign biliary stricture; SpyGlass cholangioscopy; Laser lithotripsy

**Introduction:** Endoscopic biliary stenting is a widely accepted intervention for the management of choledocholithiasis and biliary obstruction<sup>1</sup>. However, long-term retention of plastic stents can lead to serious complications including stent occlusion, recurrent cholangitis, biliary stone formation, and stricture development. Timely removal or exchange of biliary stents is therefore essential<sup>1</sup>.

Advanced endoscopic techniques such as single-operator cholangioscopy (SpyGlass system) have significantly improved the diagnostic and therapeutic capabilities in complex biliary disorders, particularly in cases involving difficult stones and indeterminate strictures<sup>3</sup>.

**Case Presentation:** A 72-year-old male initially presented in 2020 with right upper quadrant abdominal pain and jaundice of 5 days duration. Ultrasonography of the abdomen revealed multiple gallbladder calculi

and a distal CBD stone. He underwent ERCP with successful stone extraction and placement of a 10 Fr × 10 cm straight plastic biliary stent. He was advised to undergo interval laparoscopic cholecystectomy and stent removal but was lost to follow-up.

In 2024, he re-presented with fever, jaundice, and right upper quadrant pain suggestive of acute cholangitis. Clinical examination revealed right hypochondrial tenderness and mild hypotension. Laboratory evaluation showed leukocytosis and deranged liver function tests. Magnetic resonance cholangiopancreatography (MRCP) demonstrated a retained CBD stent, a mid-CBD stricture, and multiple proximal bile duct stones.

ERCP was performed, during which the occluded stent was removed and purulent bile was drained. Attempts at stone extraction were unsuccessful due to resistance at the mid-CBD stricture. A new 10 Fr × 10 cm plastic stent was placed to ensure biliary drainage. Although further evaluation with cholangioscopy was planned, the patient was again lost to follow-up.

In April 2026, he presented for the third time with biliary colic. ERCP revealed a retained old blocked stent which was removed using a snare (Figure A). Cholangiogram showed mid-CBD stricture with a filling defect. Biliary sphincteroplasty up to 12 mm was performed (Figure B). SpyGlass cholangioscopy demonstrated a smooth, benign-appearing stricture without features suggestive of malignancy such as neovascularization or mucosal irregularity. Targeted biopsies were obtained using Spybite forceps (Figure C). The stone in the mid CBD was identified and SpyGlass-guided laser lithotripsy was performed using pulsed mode (9 Hz, 1.7–2.1 J), resulting in fragmentation of the stone (Figure D). Complete duct clearance was achieved using a balloon extraction catheter and a new CBD stent was placed (Figure E).

Two days later, the patient underwent laparoscopic cholecystectomy. His postoperative course was uneventful, and he was discharged in stable condition. Stent removal was planned after 4 weeks.

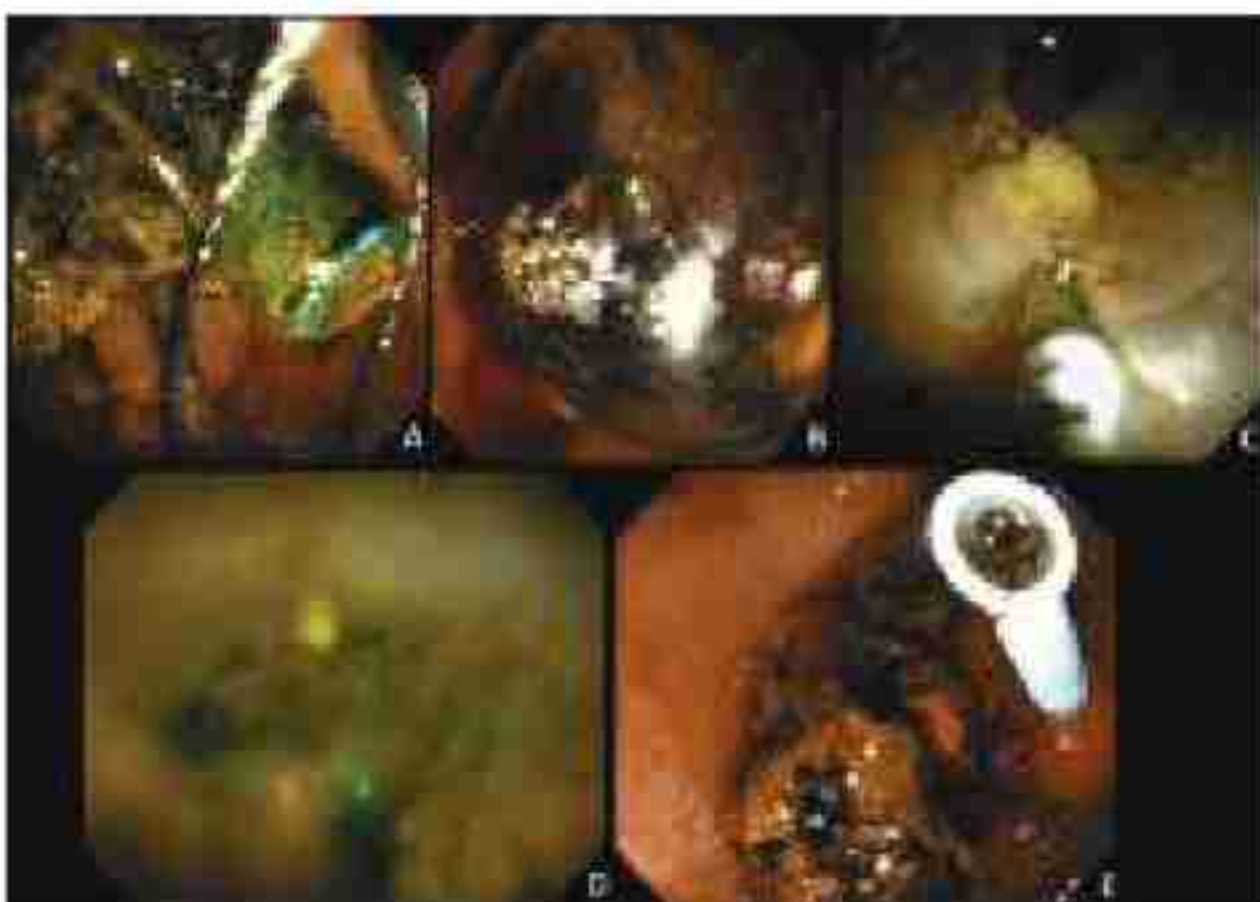
**Discussion:** Forgotten biliary stents are associated with a spectrum of complications, most notably recurrent cholangitis. Plastic stents are particularly prone to occlusion due to biofilm formation, bacterial colonization, and biliary sludge accumulation. Studies have shown that stent patency significantly decreases beyond 3–6 months, necessitating timely exchange or removal<sup>1</sup>.

In this case, prolonged stent retention led to repeated episodes of cholangitis, secondary stone formation, and development of a benign biliary stricture. The stricture was likely inflammatory in origin, resulting from chronic irritation and infection.

Management of such cases involves a stepwise approach<sup>4</sup>:

- Control of sepsis with antibiotics and biliary drainage
- Removal of infected or blocked stents
- Clearance of bile duct stones
- Evaluation of biliary strictures
- Definitive management of the underlying cause (e.g., cholecystectomy) if it was deployed.

Conventional ERCP techniques may fail in the presence of large stones proximal to strictures<sup>2</sup>. In such scenarios, cholangioscopy-guided lithotripsy provides a highly effective alternative. The SpyGlass system enables direct visualization of the biliary tree, allowing differentiation between benign and malignant strictures and facilitating targeted biopsies<sup>3</sup>.



Laser lithotripsy under direct vision has demonstrated high success rates in difficult bile duct stones, particularly when mechanical lithotripsy is unsuccessful. Further more, the ability to visually assess stricture characteristics reduces diagnostic uncertainty and guides management<sup>3</sup>. This case also underscores the importance of patient compliance and structured follow-up systems to prevent complications associated with retained stents.

**Conclusion:** Forgotten biliary stents can lead to severe complications including recurrent cholangitis, stone formation, and biliary strictures. Early recognition and timely intervention are critical. SpyGlass cholangioscopy plays a pivotal role in the management of complex biliary conditions by enabling direct visualization, targeted biopsy, and effective stone clearance using laser lithotripsy<sup>3</sup>. Strict follow-up protocols are essential to prevent such avoidable complications.

#### References

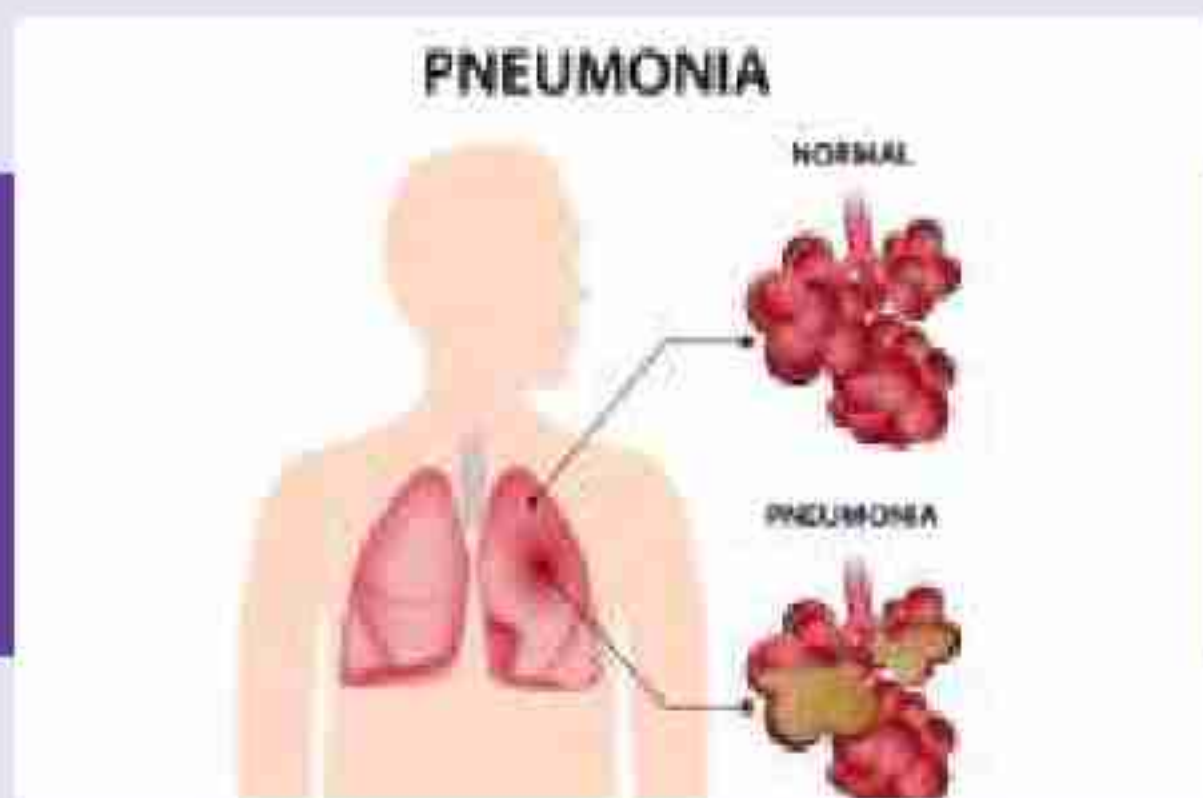
1. Dumonceau JM, et al. Biliary stenting: indications, choice of stents and results. *Endoscopy*. 2012.
2. Costamagna G, Tringali A. Current management of difficult common bile duct stones. *Gastrointest Endosc Clin N Am*. 2013.
3. Maple JT, et al. The role of cholangioscopy in biliary disease. *Gastrointest Endosc*. 2015.
4. ASGE Standards of Practice Committee. The role of ERCP in benign biliary disease. *Gastrointest Endosc*. 2015.
5. Neuhaus H, et al. Single-operator cholangioscopy for difficult bile duct stones. *Endoscopy*. 2012.
6. Reddy DN, et al. Long-term complications of biliary stents. *Indian J Gastroenterol*. 2018.
7. Sepe PS, et al. Cholangioscopy-guided lithotripsy in complex bile duct stones. *Clin Gastroenterol Hepatol*. 2011.

#### Dr. R. SABARINATHAN

MBBS, DNB(General Medicine),  
DM(Gastroenterology), FAGIE(Fellowship in  
Advanced Gastrointestinal Endoscopy)

Consultant Gastroenterologist & Hepatologist





## An uncommon cause of Pneumonia

60 year old gentleman, non smoker, presented to us with history of fever, cough with sputum production of 2 weeks duration. He was evaluated elsewhere and was diagnosed to have community acquired pneumonia treated and did not improve, hence referred to our hospital for further management. He had no history of chest pain, weight loss, hemoptysis or other non pulmonary complaints. He had history of systemic hypertension for 5 years on treatment. On evaluation he had community acquired pneumonia. Chest xray showed right mid & lower zone consolidation [Figure 1]. CECT thorax did not show any other findings other than consolidation. He was evaluated for the cause of pneumonia. Sputum for bacterial culture, AFB stain, GeneXpert were negative. Other etiological work up for pneumonia like viral, other atypical organisms were negative. Other relevant work up for consolidation negative. He was treated as per the guidelines for community acquired pneumonia. He underwent bronchoscopy and Bronchoalveolar lavage[BAL] later, for etiological work up. BAL for bacterial culture, AFB stain, GeneXpert, Nocardia, Fungal stain & culture were negative. BAL cytology showed species consistent with *brugia malayi* [Figure 2]. Later patient was treated with doxycycline [200 mg/day] for four weeks and significantly improved. Consolidation resolved [Figure 3]. Patient's symptoms resolved.

Tropical pulmonary eosinophilia is a syndrome of wheezing, fever and eosinophilia seen predominantly in the Indian subcontinent and other tropical areas. Its etiological link with *Wuchereria bancrofti* and *Brugia malayi* has been well established. But pneumonia due to *brugia malayi* very rarely reported. *Brugia malayi* is a nematode (roundworm), one of the three causative agents of lymphatic filariasis in humans. *B. malayi* is transmitted by a mosquito vector. The principal mosquito vectors include *Mansonia*, *Anopheles*, and *Aedes* mosquitoes. The geographical distribution of the disease is thus dependent on suitable mosquito breeding habitat. The disease is primarily caused by the presence of worms in the lymphatic vessels and the resulting inflammatory response of the host. Signs of infection are typically

consistent with those seen in Bancroftian filariasis—fever, lymphadenitis, lymphangitis, lymphedema, and secondary bacterial infection. The mosquito serves as a biological vector and intermediate host. *B. malayi* undergoes further development in the human as well as sexual reproduction and egg production.

Diethylcarbamazine, doxycycline, albendazole and ivermectin were the drugs used in the management of lymphatic filariasis. This case is presented due to the extreme rarity of *brugia malayi* as a cause for pneumonia in our patient. Methodical work up & accurate etiological diagnosis in patients with pneumonia is essential for the speedy recovery.

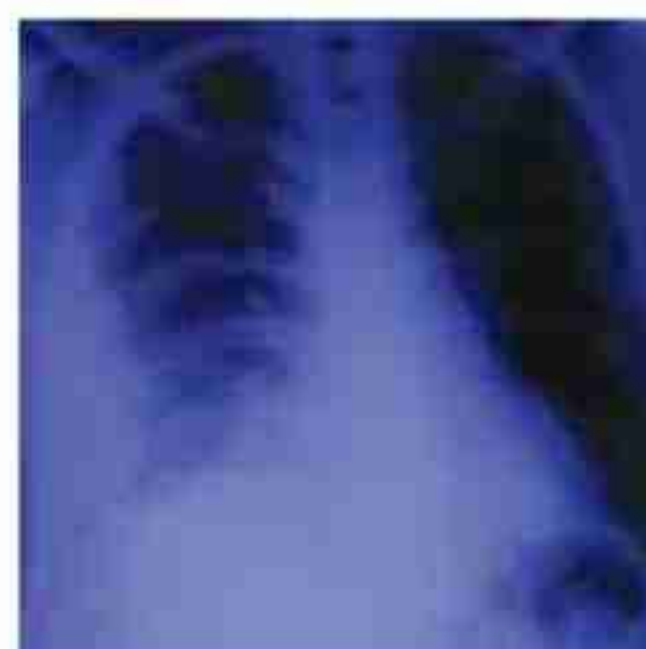

Figure 1:  
Chest Xray showing  
right mid & lower  
zone consolidation

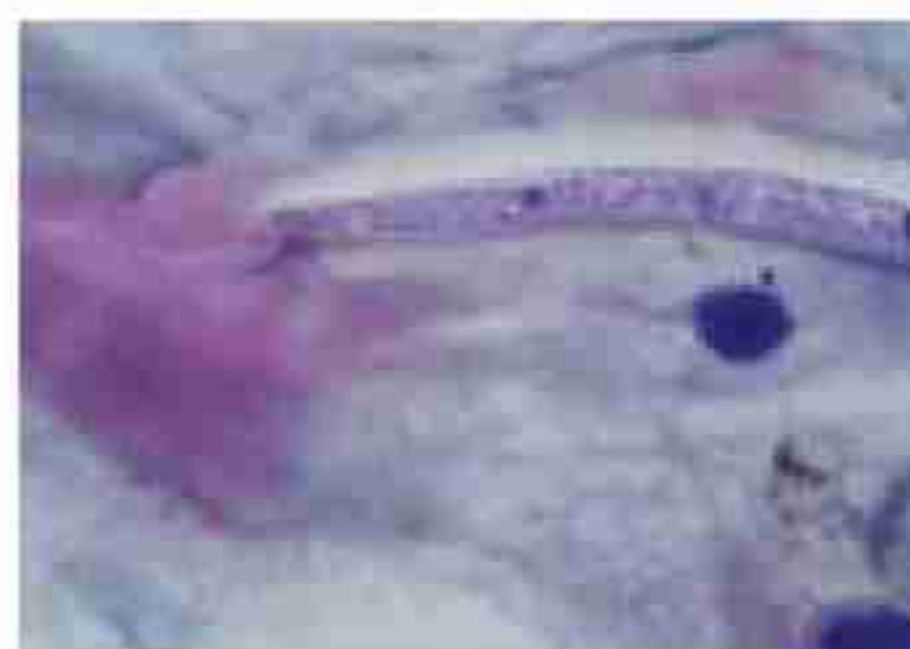

Figure 2:  
Shows *Brugia Malayi* in  
BAL cytology  
specimen

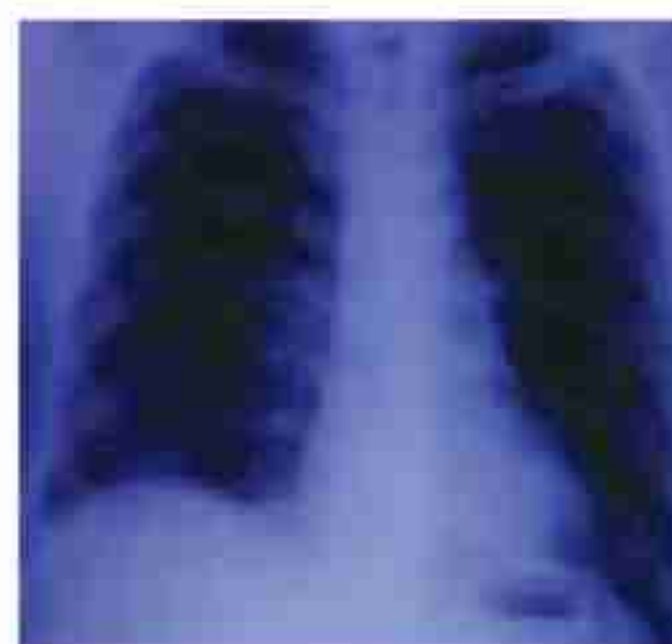

Figure 3:  
Chest Xray shows  
complete resolution  
of consolidation  
after treatment

### Dr. N. LOGANATHAN

MBBS, MD (Medicine), DM (Pulmonary,  
Critical Care & Sleep Medicine) (AIIMS), New Delhi

Senior Consultant & Interventional  
Pulmonologist & Sleep Specialist



## Pulmonary Mucormycosis

55 year old gentleman, heavy smoker with poorly controlled diabetes mellitus [HbA1C-12.5%] presented to us with history of mild hemoptysis & fever for 3 weeks duration. History of cough with mucoid sputum production present for 2 weeks. He had history of weight loss around 5 kg in the last one month. He was evaluated for the underlying etiology. Chest Xray PA view showed right lower zone thick walled cavity. CECT thorax showed right lower lobe thick walled cavity[Figure 1]. Evaluation for bacterial, viral and tubercular etiologies were negative. He was also appropriately investigated for other causes of cavitary lung disease. Patient underwent bronchoscopy later, which showed fleshy mass like lesion in the right lower lobe apical segment bronchus, biopsy of the same lesion showed features consistent with mucormycosis[Figure 2]. Patient was treated with intravenous Amphotericin B. Later patient underwent right lower lobectomy. Post operative period was uneventful. After surgery patient was treated with oral posaconazole. During the follow up period, patient was afebrile and no further episodes of hemoptysis. Blood sugar controlled. Follow up chest Xray did not show any new pathological lesions.

Mucormycosis is an opportunistic infection that is caused by Mucorales fungi of the Zygomycetes class. Mucormycosis is an invasive fungal infection usually seen in the setting of underlying immunosuppression, hematologic malignancies or poorly controlled diabetes mellitus. It can present either as localized or as disseminated disease. Rarely, the disease occurs in immunocompetent individuals also. Thoracic involvement usually presents as a non-resolving consolidation. It has worse outcomes in those with hematologic malignancies or neutropenia. It has the propensity to cause vascular invasion resulting in

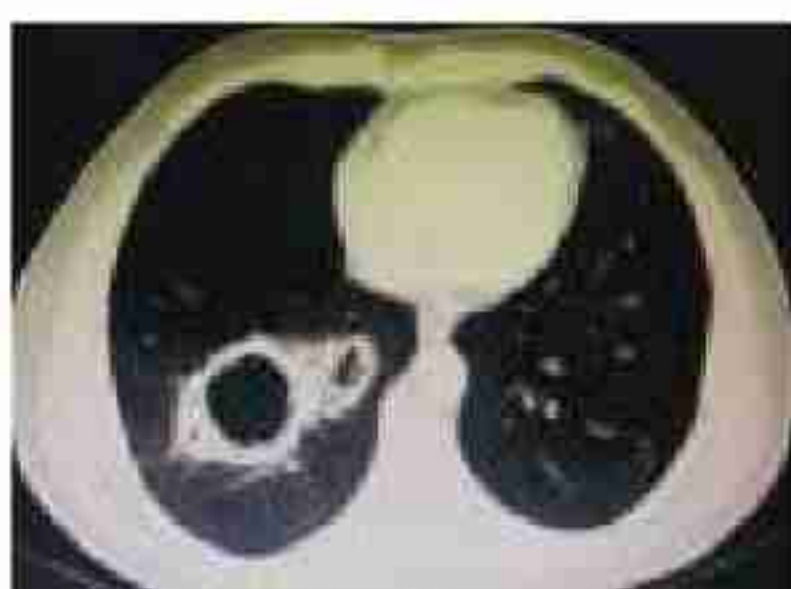

Figure 1 CECT Thorax shows right lower lobe thick walled cavity

thrombosis and tissue infarction. The symptoms of pulmonary mucormycosis are typically non-specific, even at late stages of infection and may include fever, dyspnea, coughing and chest pain. Hemoptysis commonly occurs with vascular invasion, which can occasionally be fatal. Delay in diagnosis is associated with high morbidity and mortality. The radiological manifestations of pulmonary mucormycosis are mostly non-specific. The reported findings include consolidation, cavitation, the air-crescent sign, the halo sign, the reversed halo sign, solitary or multiple pulmonary nodules or masses, bronchopleural fistulae, pulmonary artery pseudoaneurysms, lymphadenopathy and pleural effusion. Cavitation is observed in as many as 40% of cases. Histopathologically, vascular invasion with tissue necrosis and neutrophilic infiltration of the tissue is common to all types of mucormycosis. Diagnosis is achieved by demonstrating broad (diameter, 6–16  $\mu\text{m}$ ), non-septate (coenocytic), ribbon-like hyphae, with right-angled branching in a tissue biopsy specimen stained with routine hematoxylin and eosin stain. As pulmonary mucormycosis demonstrates rapid clinical progression and is often fatal, patient survival is dependent on an early diagnosis. Treatment of mucormycosis includes a combination of surgical debridement and antifungal treatment. Liposomal Amphotericin B is the antifungal of choice for initial therapy. Oral posaconazole is utilized as a step-down treatment following response to Amphotericin B. Control of the predisposing factor is essential. To prevent delays in treatment and improve the likelihood of survival, early diagnosis is imperative. Early surgical resection and amphotericin B antifungal therapy are considered the standard treatment.

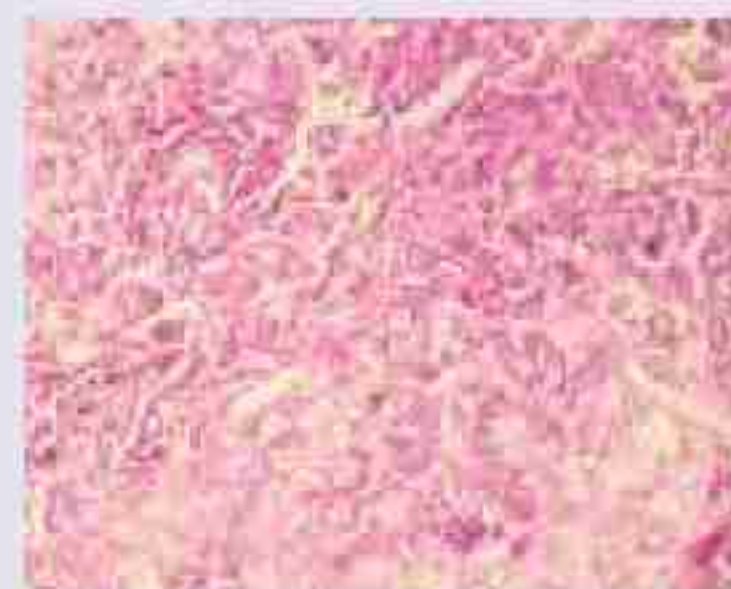

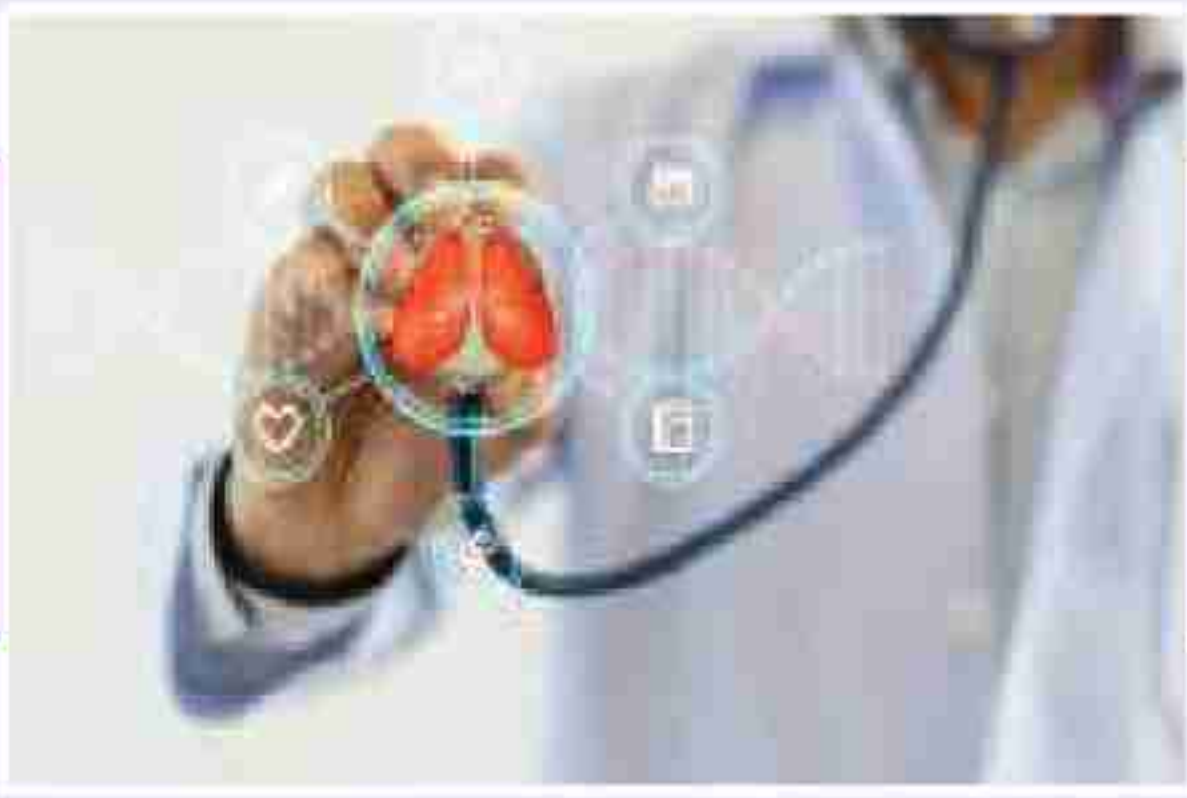Figure 2: Histopathology slide of the patient with mucormycosis demonstrating broad aseptate fungal hyphae

### Dr. N. LOGANATHAN

MBBS, MD (Medicine), DM (Pulmonary, Critical Care & Sleep Medicine) (AIIMS), New Delhi

Senior Consultant & Interventional Pulmonologist & Sleep Specialist





## The Mediastinum and Beyond: EBUS as a Precision Navigator

In respiratory medicine, few clinical scenarios generate as much diagnostic uncertainty as the patient who arrives with mediastinal lymphadenopathy on CT – or the one with a peripheral lung nodule that refuses to yield a tissue diagnosis. The reflex, for many clinicians, is to reach for CT-guided biopsy. But before that referral is made, it is worth asking: is there a safer, smarter route? At Sri Ramakrishna Hospital, our Interventional Pulmonology unit offers two complementary bronchoscopic tools that have fundamentally changed how we approach these challenges – Endobronchial Ultrasound-guided Transbronchial Needle Aspiration (EBUS-TBNA) for mediastinal and hilar lymph nodes, and Radial Probe EBUS (RP-EBUS) for peripheral lung lesions.

**EBUS-TBNA: Reaching the Mediastinum – Without a Surgical Incision:** Mediastinal lymphadenopathy is one of the commonest reasons a chest physician is consulted. The differential is broad – sarcoidosis, lymphoma, metastatic malignancy, tuberculosis, fungal infections – and tissue is almost always required to move forward. EBUS-TBNA allows real-time, ultrasound-guided needle aspiration of mediastinal and hilar lymph nodes directly through the bronchial wall, under conscious sedation. The convex probe EBUS bronchoscope visualises the lymph node in real time as the needle is deployed – ensuring precise, targeted sampling every time. The diagnostic yield for mediastinal lymphadenopathy exceeds 90% for malignant disease and is consistently high for granulomatous conditions including sarcoidosis and tuberculosis. In the same sitting, multiple nodal stations can be sampled – stations 2R, 2L, 4R, 4L, 7, 10, and 11 – providing comprehensive mediastinal staging for lung cancer without a single skin incision.

**What makes this particularly compelling is what the patient avoids:** CT-guided biopsy of mediastinal lesions carries a significant risk of pneumothorax (reported

rates of 15–30% in various series), haemorrhage, and injury to mediastinal vessels. The mediastinum is not forgiving terrain for a needle passed percutaneously through the chest wall. EBUS-TBNA, by contrast, carries a procedural complication rate of well under 1%, with no radiation exposure and no need for post-procedure observation for pneumothorax. For lung cancer staging specifically, EBUS has replaced mediastinoscopy as the first-line investigation in most international guidelines – a testament to its safety and accuracy.

**Radial EBUS: Finding the Peripheral Nodule:** The peripheral lung nodule – sitting beyond the reach of conventional bronchoscopy, yet not large or favourably positioned enough for CT-guided biopsy – is a diagnostic no man's land familiar to every pulmonologist. Radial probe EBUS addresses this gap elegantly. A miniaturised ultrasound probe is advanced through the working channel of a standard bronchoscope and guided, using fluoroscopy or CT-bronchoscopy fusion, into the peripheral bronchus leading to the target lesion. Once the probe is within or adjacent to the nodule, a characteristic "blizzard sign" appears on ultrasound – confirming probe-in-lesion position. Biopsy forceps, brushes, or needles are then advanced through the same channel for targeted sampling.

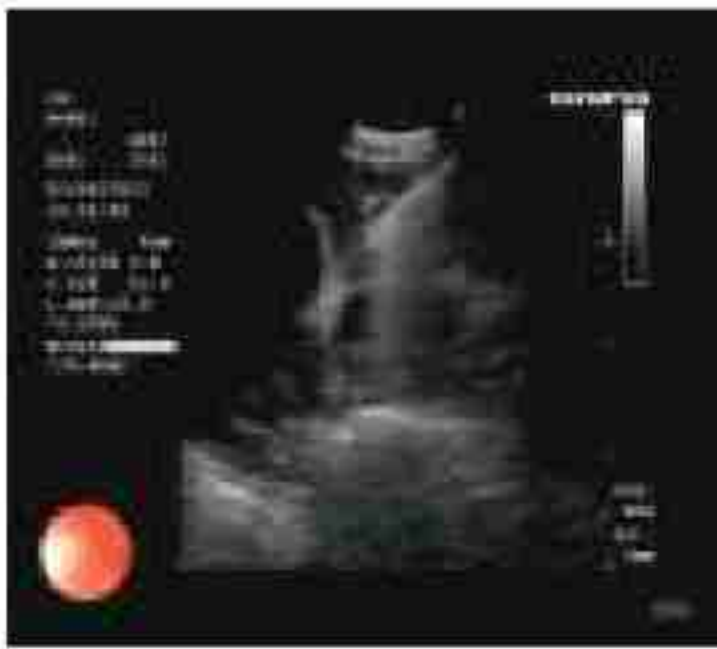The advantages over CT-guided biopsy are substantial:

- No pneumothorax risk from pleural puncture – the entire procedure is conducted endobronchially, never crossing the pleura.
- No radiation beyond the procedural fluoroscopy – compared to the multiple CT acquisitions required to guide and confirm each needle pass in a CT-guided procedure.
- No post-procedure observation for pneumothorax – patients typically return to the ward or home within the hour.
- Simultaneous airway assessment – the bronchoscope evaluates the entire airway in the same sitting, identifying any endobronchial component not visible on imaging.

Diagnostic yield for radial EBUS in peripheral nodules ranges from 65–80% in experienced hands, and approaches 85–90% when combined with navigational bronchoscopy or virtual bronchoscopy guidance. For nodules that have a bronchus sign on CT – a bronchus directly leading into the lesion – the yield is particularly high.

**A Practical Note on CT-Guided Biopsy:** CT-guided percutaneous biopsy remains a valuable tool, particularly for pleural-based, chest wall, or subpleural lesions where bronchoscopic access is genuinely limited. We work closely with our interventional radiology colleagues and refer appropriately.

However, for mediastinal lymphadenopathy and for peripheral nodules with a bronchus sign or in patients with impaired lung function, the risk-benefit calculus clearly favours the bronchoscopic route. The risks of CT-guided biopsy – pneumothorax requiring intercostal drainage in a subset of patients, haemoptysis, haemorrhage, and the cumulative radiation from multiple CT acquisitions during the procedure – are not trivial, particularly in patients who are already physiologically compromised by their underlying lung disease.



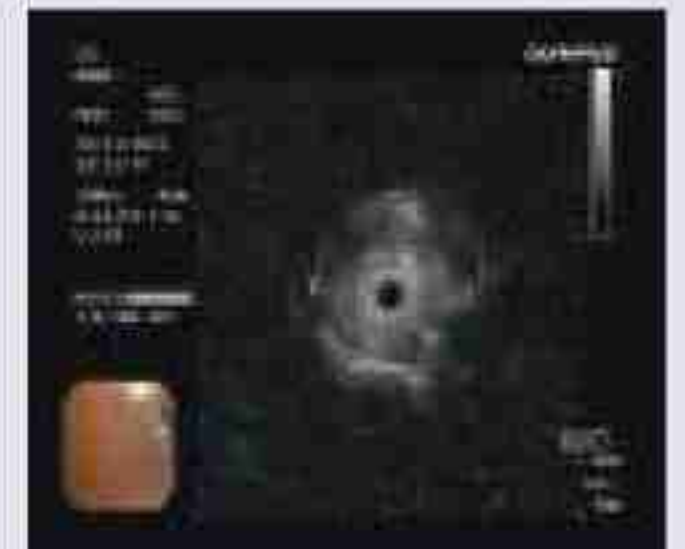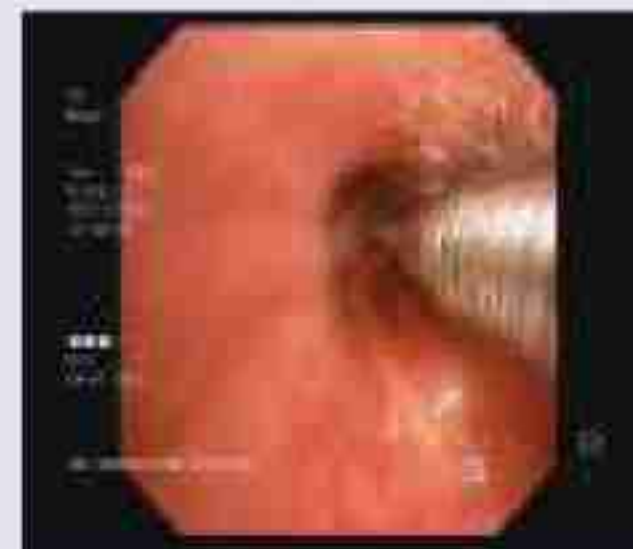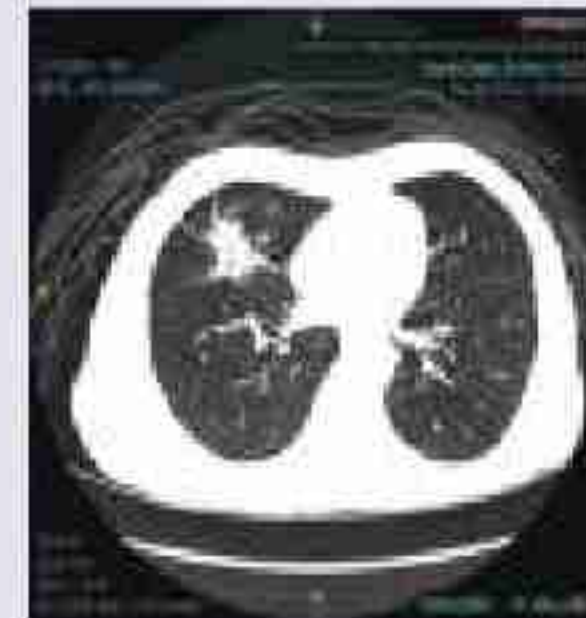**Figure 1:** EBUS sonoanatomy of the mediastinum – Olympus convex probe EBUS at 10MHz. Real-time ultrasound guidance allows precise needle targeting of mediastinal lymph nodes under direct visualisation, while simultaneously delineating adjacent vascular structures – ensuring the needle trajectory avoids the pulmonary artery, aorta, and other mediastinal vessels at all times. This intrinsic vascular awareness is a defining safety advantage over blind or CT-guided percutaneous



**Figure 2:** EBUS-TBNA in progress — the interventional pulmonologist navigates the convex probe bronchoscope under real-time Olympus ultrasound guidance (inset, top right) while the assistant advances the transbronchial needle through the working channel for targeted lymph node sampling. The simultaneous visualisation of nodal tissue and adjacent mediastinal vasculature on the ultrasound screen ensures precise, safe needle deployment — all performed under conscious sedation, without a skin incision, and with negligible risk of vascular or pleural injury.

The question to ask at the point of referral is not "can CT-guided biopsy reach this lesion?" but "is there a safer path to the same answer?" In the majority of cases involving mediastinal nodes or peripheral nodules with a bronchus sign, bronchoscopic EBUS is that path.

**Refer Early. Think EBUS:** As with any other procedure, timing matters. For mediastinal lymphadenopathy, early EBUS-TBNA provides tissue diagnosis and staging simultaneously – avoiding the need for separate procedures. For peripheral nodules, early radial EBUS avoids an inadvertent pneumothorax in a patient who may have little respiratory reserve to spare. Our unit at Sri Ramakrishna Hospital offers both EBUS-TBNA and radial probe EBUS as day-care procedures under conscious sedation, with same-day discharge in the majority of cases. Rapid ROSE (Rapid On-Site Evaluation) with cytopathology support ensures adequacy of samples in real time. Precision tissue diagnosis. Minimal risk. No radiation penalty.



**Figure 3 (1):** CT thorax (lung window) demonstrating a right lung middle lobe mass with peribronchial extension — a lesion anatomically accessible via radial probe EBUS given its relationship to the segmental bronchi. The bronchus sign, where a bronchus is seen leading directly into the lesion, predicts favourable yield with bronchoscopic sampling and obviates the need for percutaneous CT-guided biopsy with its attendant risks of pneumothorax and haemorrhage.

**Figure 3 (2):** Bronchoscopic view of the Olympus radial miniprobe being navigated into the peripheral bronchus subtending the target lesion under direct vision — following the roadmap established by the CT.

**Figure 3 (3):** The corresponding 360° radial ultrasound image at 20MHz (Olympus, SCL 5mm) confirming probe-in-lesion position by the characteristic circumferential echogenic pattern. Targeted biopsies were subsequently obtained through the same working channel — without pleural puncture, without pneumothorax risk, and without the cumulative radiation burden of multiple CT acquisitions required during percutaneous guidance.

**Dr. ARUN GANGADHAR**

MBBS, DNB (Respiratory Medicine), MNAMS, IDCCM (Critical care), European Diploma in Respiratory Medicine, Fellowship in Advanced Interventional Pulmonology (Malaysia)

**Consultant Interventional Pulmonologist & Sleep Physician**



# Sri Ramakrishna Hospital

## HEALTH AWARENESS EXHIBITION (PULMONOLOGY & MEDICAL GASTROENTEROLOGY)

@ BROOKEFIELDS MALL - 16.05.2026 & 17.05.2026

Sri Ramakrishna Hospital organized a two-day interactive health awareness exhibition at Brookefields Mall, Coimbatore, on May 16 and 17, 2026, in observance of World Asthma Day and World Digestive Health Day. The initiative was aimed at creating greater public awareness about respiratory and digestive health through engaging and educational activities outside the traditional hospital environment. By bringing healthcare awareness directly into a public space, the hospital successfully encouraged



meaningful conversations on preventive care, lifestyle management, and early diagnosis. The exhibition was inaugurated by Dr. Sundar Ramakrishnan, Managing Trustee of SNR Sons Charitable Trust, in the presence of Shri. C. V. Ramkumar, Chief Executive Officer, Shri. D. Mahesh Kumar, Chief Administrative Officer of SNR Sons Charitable Trust, Dr. S. Rajagopal, Medical Director, and Dr. S. Alagappan, Medical Superintendent of Sri Ramakrishna Hospital. The event also witnessed the participation of principals, faculty members, and students from the Allied Health Sciences institution, whose active involvement added immense value to the awareness initiative. A major highlight of the exhibition was the innovative working models and interactive displays developed by the Allied Health Sciences students. The exhibits simplified complex medical concepts related to pulmonology and gastroenterology, helping visitors better understand symptoms, prevention methods, and the importance of healthy lifestyle choices. Through this impactful outreach initiative, Sri Ramakrishna Hospital once again reaffirmed its commitment to community healthcare education and social responsibility while continuing to lead the region in advanced medical care and patient-centered awareness programs.



**SRI RAMAKRISHNA  
HOSPITAL**



395, Sarojini Naidu Road, Siddhapudur, Coimbatore

**For appointments: 0422 - 4500 000 / 3500 000**

info@sri Ramakrishnahospital.com | www.sri Ramakrishnahospital.com

Visit us @  / Sri Ramakrishna Hospital